

## MODULE 10.5

## Clinical Studies and Treatment Data - DRCR.net Protocol I

## DRCR.net: Protocol I

Study Name	Randomized Trial Evaluating Ranibizumab Plus Prompt or Deferred Laser or Triamcinolone Plus Prompt Laser for Diabetic Macular Edema
Purpose of study	Evaluate intravitreal 0.5-mg ranibizumab or 4-mg triamcinolone combined with focal/grid laser compared with focal/grid laser alone for treatment of diabetic macular edema (DME)
Study authors	Elman MJ, Aiello LP, Beck RW, Bressler NM, Bressler SB, Edwards AR, Ferris FL, Friedman SM, Glassman AR, Miller KK, Scott IU, Stockdale CR, Sun JK et al for The Diabetic Retinopathy Clinical Research Network
Published in	<i>Ophthalmology</i> . 2010;117:1064–1077.
Study also known as	Protocol I
Subsequent studies	<p>Elman MJ, Aiello LP, Beck RW, Bressler NM, Bressler SB, Edwards AR, Ferris FL, Friedman SM, Glassman AR, Miller KK, Scott IU, Stockdale CR, Sun JK et al for The Diabetic Retinopathy Clinical Research Network. Expanded 2-Year Follow-up of Ranibizumab Plus Prompt or Deferred Laser or Triamcinolone Plus Prompt Laser for Diabetic Macular Edema. <i>Ophthalmology</i>. 2011;118:609-614.<sup>2</sup></p> <p>Elman MJ, Qin H, Aiello LP, Beck RW, Bressler NM, Ferris FL, Glassman AR, Maturi RK, Melia M on behalf of the Diabetic Retinopathy Clinical Research Network. Intravitreal ranibizumab for diabetic macular edema with prompt versus deferred laser treatment: Three-year randomized trial results. <i>Ophthalmology</i>. 2012;119:2312–2318.<sup>3</sup></p> <p>Elman MJ, Ayala A, Bressler NM, et al. Intravitreal Ranibizumab for Diabetic Macular Edema with Prompt versus Deferred Laser Treatment: 5-Year Randomized Trial Results. <i>Ophthalmology</i>. 2015;122(2):375-381.<sup>4</sup></p>

## Study Overview

The Diabetic Retinopathy Clinical Research Network (DRCR.net) has undertaken dozens of clinical studies evaluating numerous potential treatment regimens. The investigators represent a geographically diverse number of centers throughout the US. One of the earlier studies the group undertook was to determine if either intravitreal

triamcinolone with focal/grid photocoagulation or ranibizumab with focal/grid photocoagulation was more effective than laser alone (with sham injections). DRCR Protocol I was a phase 3, multicenter, randomized study conducted at 52 clinical centers in the United States. Eyes were randomized to sham

injection + prompt laser (n = 293), 0.5-mg ranibizumab + prompt laser (n = 187), 0.5- mg ranibizumab + deferred ( $\geq 24$  weeks) laser (n = 188), or 4-mg triamcinolone + prompt laser (n = 186). Retreatment followed an algorithm facilitated by a web-based, real-time data-entry system. Patients received the study drug or sham injection every 4 weeks through the 12-week study visit. This study allowed bilateral eye enrollment, with the following dictates: the right eye was randomly assigned first; if the right eye was assigned to any group but laser only, the left eye was assigned to the laser-only group. If the right eye was assigned to the laser-only group, the left eye was assigned to one of the remaining 3 combination groups. Baseline characteristics were similar among all groups, with a mean best-corrected visual acuity (BCVA) Early Treatment Diabetic Retinopathy Study (ETDRS) letter score of  $63 \pm 12$  and a mean baseline optical coherence tomography (OCT) central subfield thickness of  $405 \pm 134 \mu\text{m}$  in each group.

The primary outcome was the mean change in BCVA at 1 year although the study was planned for a total of 3 years.<sup>1</sup> After the first year, visits occurred every 4 to 16 weeks, depending on the treatment group, disease course, and treatment administered. At the primary endpoint (1 year), sham injections were discontinued. Secondary endpoints included mean change in OCT-measured central subfield thickness and safety (ocular and systemic adverse events).

After baseline treatment, patients were treated every 4 weeks through the 12-week study visit. Beginning at the 16-week study visit, retreatment was at the investigator's discretion if the patient was deemed a "success;" at 24 weeks and onward, retreatment was at investigator discretion if there was "no improvement." When retreatment with a study drug or sham injection was indicated, eyes assigned to 1 of the ranibizumab groups could receive

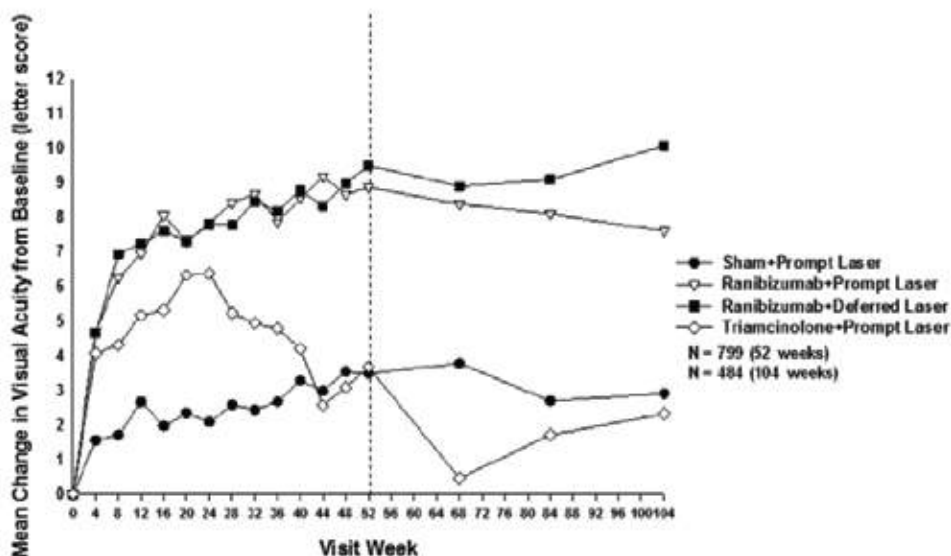


Figure 1: Mean change in visual acuity at follow-up visits.

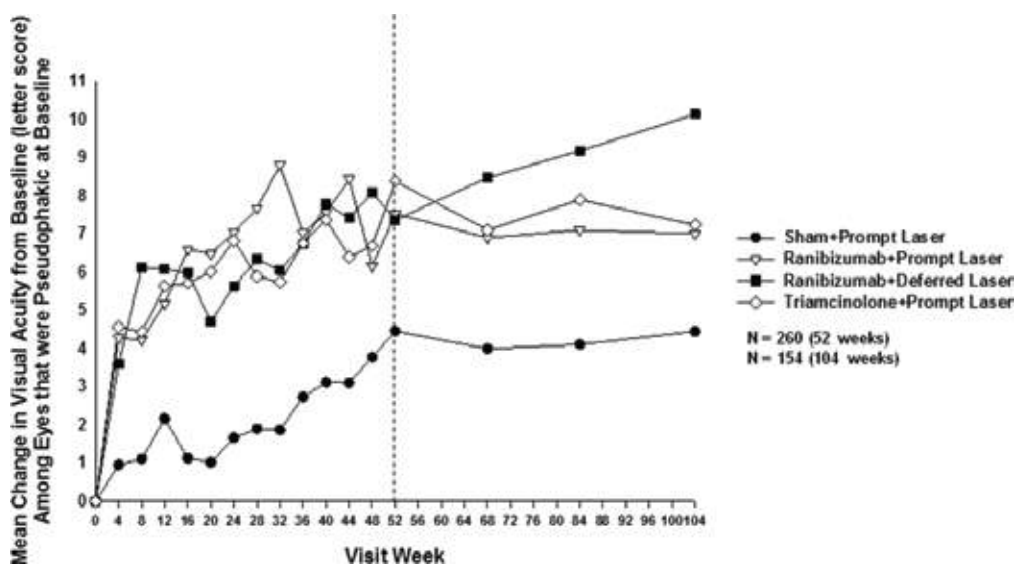


Figure 2: Mean change in visual acuity in subset of pseudophakic eyes.<sup>1</sup>

ranibizumab as often as every 4 weeks; eyes assigned to intravitreal triamcinolone could receive triamcinolone as often as every 16 weeks with sham injections as often as every 4 weeks in between triamcinolone injections.

The 2 ranibizumab arms had superior outcomes to either sham + sham laser or triamcinolone + prompt laser.<sup>1</sup> About half the eyes gained  $\geq 10$  ETDRS letters, and about 30% gained  $\geq 15$  ETDRS letters. These findings held regardless of when laser treatment was added. Conversely, the triamcinolone + prompt laser arm did not produce superior findings to the laser-only group. Contralateral effects when both eyes were enrolled were negligible. However, a subset analysis of pseudophakic eyes found visual outcomes similar to those in the ranibizumab group, suggesting that cataract may have an impact on outcomes separate from the DME (see Figures 1 and 2).

All eyes showed an improvement in retinal thickness from baseline, with the three combination arms showing better improvement than the laser-only group. See Figure 3.

The 2-year follow-up results showed ranibizumab was more efficacious than sham injections at improving vision and preventing further vision loss.<sup>2</sup> The 36-month results supported those findings as well, with ranibizumab + deferred laser resulting in better BCVA ETDRS letter scores than ranibizumab + prompt laser (9.7 letters vs 6.8 letters, respectively)<sup>3</sup> (see Figure 3).

Investigators concluded that intravitreal ranibizumab with prompt or deferred laser was more effective than either triamcinolone plus prompt laser or laser alone in center-involved DME. In pseudophakic eyes, however, intravitreal triamcinolone plus prompt laser results in similar vision gains as either ranibizumab arm, but frequently increased the risk of elevating intraocular pressure (IOP). The most recent publication in this series followed patients out to 5 years: 124 patients in the prompt laser group and 111 patients in the deferred laser group were evaluated.<sup>4</sup>

At 5 years, the study authors said results suggested there was basically no difference between prompt laser or deferring laser for at least 24 weeks when initiating intravitreal ranibizumab treatment for DME. Most eyes treated with laser (regardless of timing) maintained vision gains achieved in the first year through year 5, and more than half the patients did not need additional injections during year 5.<sup>4</sup>

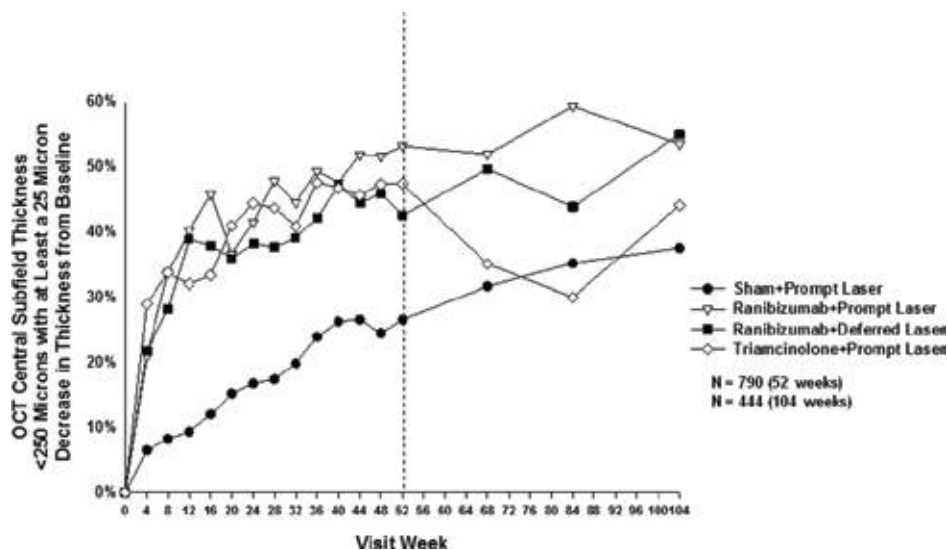
## Study Implications

The DRCR.net investigators were the first to evaluate focal/grid laser in eyes with center-involved DME and found about one-third of patients gained 2 lines of vision over the course of 2 years, but another 20% lost 2 lines of vision during the same time. It has been a long-held belief that the DRCR.net's early work is what provided the impetus to research alternative therapies for the treatment of DME. Protocol I was the first to directly compare an anti-VEGF to a corticosteroid, although both treatment arms also included either prompt or deferred laser, and this study also compared those combination treatments to steroid alone.

This study was the first to show ranibizumab plus laser was superior to laser alone; the longer term analyses confirmed these findings and further differentiated between the ranibizumab arms to find ranibizumab with deferred laser had better visual outcomes.<sup>3</sup> This study also underscored the issue with corticosteroids and concerns about IOP elevations.

## Take-Home Points

- Ranibizumab produced better visual acuity gains than triamcinolone or laser alone.
- After 3 years, ranibizumab with deferred laser produced the best visual acuity outcomes compared to triamcinolone plus prompt laser, ranibizumab plus prompt laser, or laser alone.
- Elevations in IOP are noted in the triamcinolone group and not in the ranibizumab group.



**Figure 3:** Optical coherence tomography central subfield thickness <250 microns with at least a 25 micron change from baseline. <sup>1</sup>

## References

1. Diabetic Retinopathy Clinical Research Network, Elman MJ, Aiello LP, et al. Randomized trial evaluating ranibizumab plus prompt or deferred laser or triamcinolone plus prompt laser for diabetic macular edema. *Ophthalmology*. 2010;117:1064-1077.e35.
2. Elman MJ, Bressler NM, Qin H, et al. Expanded 2-year follow-up of ranibizumab plus prompt or deferred laser or triamcinolone plus prompt laser for diabetic macular edema. *Ophthalmology*. 2011;118:609-614.
3. Diabetic Retinopathy Clinical Research N, Elman MJ, Qin H, et al. Intravitreal ranibizumab for diabetic macular edema with prompt versus deferred laser treatment: three-year randomized trial results. *Ophthalmology*. 2012;119:2312-2318.
4. Elman MJ, Ayala A, Bressler NM, et al. Intravitreal Ranibizumab for Diabetic Macular Edema with Prompt versus Deferred Laser Treatment: 5-Year Randomized Trial Results. *Ophthalmology*. 2015;122:375-381.