MODULE 10.4
Clinical Studies and Treatment Data - BOLT

BOLT[1]

Study Name	A Prospective Randomized Trial of Intravitreal Bevacizumab or Laser Therapy in the Management of Diabetic Macular Edema (BOLT Study) 12-Month Data: Report 2
Purpose of study	To compare intravitreal bevacizumab to a modified Early Treatment Diabetic Retinopathy Study (ETDRS) macular laser therapy in patients with clinically significant macular edema (CSME)
Study authors	Michaelides M, Kaines A, Hamilton RD, Fraser-Bell S, Rajendram R, Quhill F, Boos CJ, Xing W, Egan C, Peto T, Bunce C, Leslie RD, Hykin PG.
Published in	*Ophthalmology. 2010;117:1078-1086.*
Study also known as	BOLT
Subsequent studies	Sivaprasad S, Crosby-Nwaobi R, Esposti S, et al. Structural and functional measures of efficacy in response to bevacizumab monotherapy in diabetic macular oedema: Exploratory analyses of the BOLT study. Report 4. PLoS One. 2013;8(8):e72755. doi:10.1371/journal.pone.00727552 Rajendram R, Fraser-Bell S, Kaines A, et al. A 2-year prospective randomized controlled trial of intravitreal bevacizumab or laser therapy (BOLT) in the management of diabetic macular edema. Arch Ophthalmol. 2012;130(8):972-997.3

Study Overview

Study investigators had noted that several small, uncontrolled studies evaluating bevacizumab found a purported beneficial effect in the treatment of DME. As such, they undertook a direct comparison (open-label) study.

Patients enrolled in the BOLT study had central subfield thickness measured by optical coherence tomography (OCT) of ≥270 µm and at least 1 prior laser treatment. The study was conducted in London at Moorfields Eye Hospital and enrolled 80 patients with a best-corrected visual acuity (BCVA) in the study eye between 35 and 69 ETDRS letters (Snellen equivalent between 6/12 and 6/60). Moorfields also compounded the bevacizumab from 1.25 mg in 0.05 ml to a prefilled syringe of 0.13 ml.[1] Subjects also had to have confirmed center-involving CSME with central macular thickening (CMT) on OCT of at least 270 µm.[1] Exclusion criteria included macular ischemia (foveal avascular zone of > 1000 µm greatest linear dimension or severe perifoveal intercapillary loss on fundus fluorescein angiography), any treatment for DME within the previous 3 months, panretinal photocoagulation within the previous 3 months or anticipated in the following 6 months, and proliferative diabetic retinopathy (DR) except for tufts of new vessels elsewhere less than 1 disc in area with no vitreous hemorrhage.

Patients were randomized to either intravitreal bevacizumab 1.25-mg injections every 6 weeks (n = 42) or to laser therapy every 4 months (n = 38). Patients were eligible for laser retreatment if the study eye met ETDRS criteria. Patients were eligible for bevacizumab retreatment based on an OCT protocol:

at 4.5 months if CMT was less than 270 µm, bevacizumab was given if macular thickness was not considered "stable;" if CMT was more than 270 µm at any follow-up after 4.5 months, bevacizumab was administered until the treating physician deemed there to be a "stable" macular thickness. "Stable" thickness was defined as 3 consecutive visits with a CMT within 20 µm of the patient's thinnest CMT.[1]

The primary endpoint was the mean change in BCVA at 12 months; numerous secondary endpoints were evaluated as well. Among them were mean change in CMT between the 2 groups, mean change in CMT, and the proportion of patients who gained or lost ETDRS letters.[1]

At 12 months, the bevacizumab group gained a median of 8 ETDRS letters, whereas the laser group lost a median of 0.5 ETDRS letters (P = .0002). See Figure 1 for the ETDRS gains in months 12 and 24.[1,3] Similar outcomes were reported in the proportion of patients who gained, lost, or maintained vision. In the bevacizumab group, 11.9% gained at least 15 ETDRS letters, compared to 5.3% in the laser group; 31% of those in the bevacizumab group gained at least 10 ETDRS letters compared to 7.9% in the laser arm. None of the patients in the bevacizumab arm lost more than 30 ETDRS letters, but 2 patients in laser group (5.3%) lost more than 30 ETDRS letters.

Similarly, anatomical outcomes were significantly better in the bevacizumab arm. CMT in the bevacizumab group decreased from a baseline of 507 µm to 378 µm at 12 months; in the laser arm, CMT decreased from 481 µm to 413 µm.

Study Implications

Trial data supports the use of bevacizumab even in patients with previous long histories of CSME and in those with a high number of previous laser treatments. Although these results were considerably better in the modified laser group than had been reported with traditional laser, they still paled in comparison to the bevacizumab results. This study adds to the increasing evidence of a benefit of using bevacizumab to treat CSME.[1] Additionally, these results were reported with an every-6-week dosing regimen; other anti-VEGFs are approved for monthly dosing. The visual outcomes attained by the patients in the bevacizumab arm were similar to those reported in other studies that evaluated ranibizumab.[3] However, it is important to reiterate that bevacizumab is not approved for ocular use; it must be compounded for intravitreal injection, and although the potential visual benefits should not be ignored, they should be weighted against the additional risks associated with compounding.

The authors suggested that earlier intervention with bevacizumab would result in "even better visual outcomes," and that the rapid reduction in macular edema (when compared to laser) "may lead to superior longer-term visual acuity."[1] Results from the 2-year study confirmed these initial 12-month study findings. Further, the 24-month results noted patients were injected a mean of 13 times during the course of the 24-month study; patients in the laser group only underwent 4 treatments in the same 24 months.[3]

The BOLT study is visualized at the end of this module.

Take-Home Points

- Compared to using a modified macular laser treatment regimen, bevacizumab dosed every 6 weeks produced better visual and anatomical outcomes in patients with CSME.
- One-year outcomes favoring bevacizumab were sustained over 24 months.
- Visual benefits should be weighed against the small inherent risks of compounding pharmaceuticals.
- Study results were in line with others that evaluated ranibizumab for the treatment of DME.

References

1. Michaelides M, Kaines A, Hamilton RD, et al. A prospective randomized trial of intravitreal bevacizumab or laser therapy in the management of diabetic macular edema (BOLT study) 12-month data: report 2. *Ophthalmology*. 2010;117(6):1078-86 e2.

2. Sivaprasad S, Crosby-Nwaobi R, Esposti S, et al. Structural and Functional Measures of Efficacy in Response to Bevacizumab Monotherapy in Diabetic Macular Oedema: Exploratory Analyses of the BOLT Study (Report 4). *PLoS One*. 2013;8(8):e72755.

3. Rajendram R, Fraser-Bell S, Kaines A, et al. A 2-year prospective randomized controlled trial of intravitreal bevacizumab or laser therapy (BOLT) in the management of diabetic macular edema: 24-month data: report 3. *Arch Ophthalmol.* 2012;130(8):972-9.

The Angiogenesis Foundation

BOLT May 2007 - August 2009

A prospective randomized trial of intravitreal *B*evacizumab *O*r *L*aser *T*herapy in the management of diabetic macular edema

Phase 2

NHS National Health Service Foundation Trust

LONDON, U.K.
Moorsfields Eye Hospital

STUDY POPULATION

80 eyes, from 80 patients

INCLUSION CRITERIA

- Center-involving Clinically Significant Diabetic Macular Edema (CSME)
- Central Macular Thickness (CMT) on Ocular Coherence Tomography (OCT) ≥270 µm
- Best-corrected Visual Acuity (BCVA) 35≤ x ≤69 Letters on Early Treatment of Diabetic Retinopathy Study (ETDRS) Chart
- At least 1 prior MLT

TRIAL AGENT

Bevacizumab (Intravitreal Bevacizumab Injection (IBI)) VS Laser (Macular Laser Therapy (MLT))

ENDPOINTS (measured at months 12 and 24)

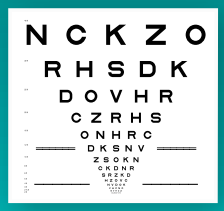

Mean BCVA in ETDRS Letters

TRIAL DESIGN

Double-Blind

- Bevacizumab (IBI)
- Laser (MLT)
- Repeating Regimen

*** Laser (MLT) Retreatment:** After the initial modified ETDRS MLT given at Baseline, patients were reassessed every 4 months and with end-of-year 12- and 24-month visits. Laser was given if the study eye met ETDRS criteria.

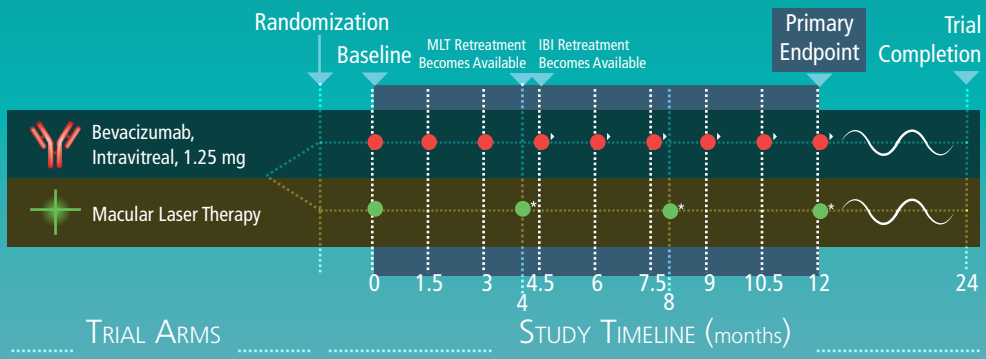

▸ Bevacizumab (IBI) Retreatment: After the initial three bevacizumab injections at Baseline and at 1.5- and 3-month visits, patients were reassessed every 1.5 months and with end-of-year 12- and 24-month visits. Bevacizumab was given based on an OCT retreatment protocol: At 4.5 months, if CMT was < 270 µm, then bevacizumab was given if macular thickness was considered not "stable." If, at 4.5 months and subsequent visits, CMT was >270 µm, then bevacizumab was given until a "stable" macular thickness was achieved. A "stable" thickness was defined as 3 consecutive visits with a CMT within 20 µm of the patient's thinnest CMT. The total bevacizumab injections received in one year were at minimum, 3, and at maximum, 9.

RESULTS

Bevacizumab intravitreal injection proved more efficacious in improving vision loss for a greater number of people compared to laser.

- Bevacizumab (IBI)
- Laser (MLT)

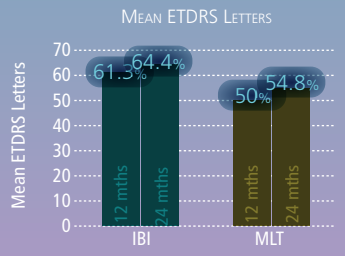

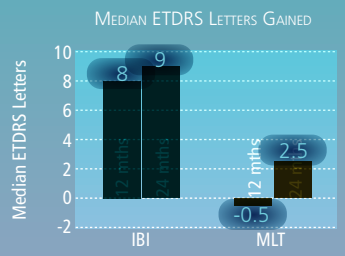

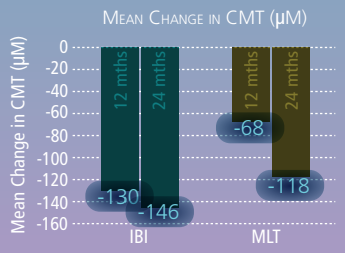

IMPACT

Trial data supports the use of bevacizumab, the most commonly used anti-VEGF agent globally.

- Demonstration of efficacy in patients despite long histories of CSME and in those with a high number of previous laser treatments.

SUPERIOR OUTCOMES using

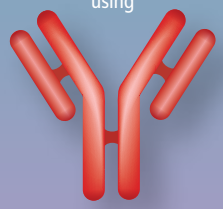

BEVACIZUMAB

* SOURCE - Michaelides M. et al. A prospective randomized trial of intravitreal bevacizumab or laser therapy in the management of diabetic macular edema (BOLT study) 12-month data: report 2. *Ophthalmology.* 2010 Jun;117(6):1078-1086.e2. doi: 10.1016/j.ophtha.2010.03.045. Epub 2010 Apr 22.

* SOURCE - Ranjendram R. et al. A 2-Year Prospective Randomized Controlled Trial of Intravitreal Bevacizumab or Laser Therapy (BOLT) in the Management of Diabetic Macular Edema. *Arch Ophthalmol*. 2012 Aug;130(8):972-9.