MODULE 6.11
Retinal Changes and Edema

Diabetic retinopathy (DR) is assessed clinically by observation of changes in the retina. Diabetic eye disease is classified by severity, from no microvascular lesions (no retinopathy) to mild, moderate, or severe nonproliferative diabetic retinopathy (NPDR) to proliferative diabetic retinopathy (PDR). Hallmarks of NPDR include microaneurysms, intraretinal hemorrhages, and intraretinal microvascular abnormalities. Hallmarks of PDR include neovascularization of the optic disc or elsewhere, and preretinal or vitreous hemorrhage.[1] This material will be covered in more depth in Module 7.

Macular edema, one of the most common causes of vision loss in diabetic eye disease, can develop at any stage of DR and is assessed separately from the stages of retinopathy. Clinically significant macular edema (CSME) is defined as retinal thickening within 500 µm of the fovea, hard exudates (lipid deposits) within 500 µm of the fovea plus adjacent retinal thickening, or retinal thickening of greater than 1 optic disc area within 1 optic disc diameter of the fovea.[1]

Vision loss results both from neovascularization of the retina and from the sequelae of diabetic retinal vessel changes including ischemia and edema.[1] Vascular endothelial growth factor (VEGF) is implicated in all of these pathogenic effects: it promotes angiogenesis, causes breakdown of the blood-retinal barrier, stimulates growth of endothelial cells and neovascularization, and increases vascular permeability.[2]

Clinically Significant DME

Retina - Fundus View

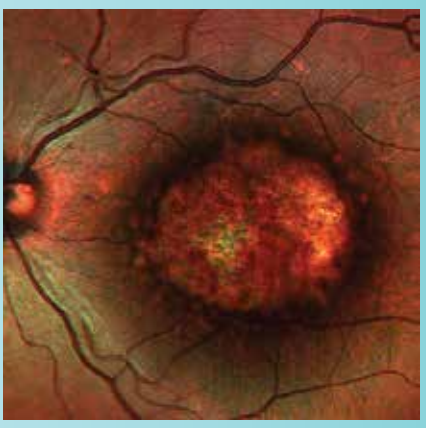

Microaneurysms
Dot and blot hemorrhages
Flame-shaped hemorrhages
Retinal edema and hard exudates
Cotton-wool spots
Venous loops and venous beading
Macular edema
Intraretinal microvascular abnormalities

Macula - OCT view

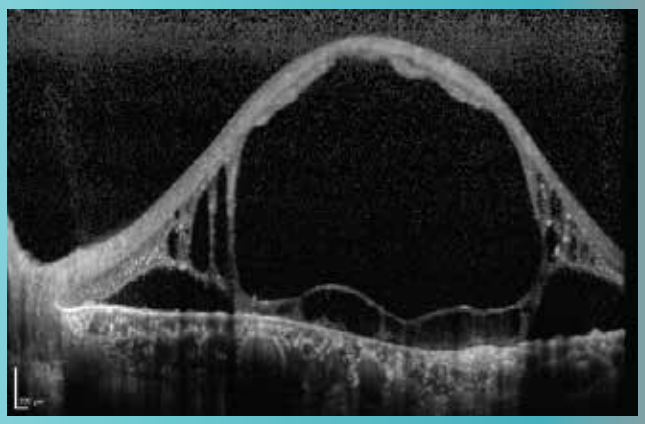

Retinal thickening at or within 500 microns from the center of the macula; hard exudates at or within 500 microns from the center of the macula with thickening of the adjacent retina; an area or areas of retinal thickening at least 1 disk area or larger in size, any part of which is within 1 disk diameter of the center of the macula.

References

1. Cheung N, Mitchell P, Wong TY. Diabetic retinopathy. *Lancet.* 2010;376:124-136.

2. Tarr JM, Kaul K, Chopra M, Kohner EM, Chibber R. Pathophysiology of diabetic retinopathy. *ISRN Ophthalmol.* 2013;2013:343560.