MODULE 4.4
The Role of Blood Vessels in Diabetic Ocular Disease

Blood vessels play a major role in diabetic ocular disease, including diabetic retinopathy (DR) and diabetic macular edema (DME). One hallmark of DR and DME is change in the retinal microvasculature.

In DR, excessive release of vascular endothelial growth factor (VEGF) induces damaging changes to the retinal microvasculature. Retinal microvascular dysfunction in diabetes is generally characterized by microaneurysms (MAs), intraretinal hemorrhages (resulting from ruptured small vessels and MAs), hard exudates (extracellular accumulations of lipids, proteins, and lipoproteins derived from leakage from abnormal vessels), macular edema, capillary occlusion, and neovascularization.[1,2] Whereas nonproliferative DR involves intraretinal microvascular dysfunction or abnormalities, proliferative DR involves growth of abnormal new blood vessels. VEGF plays crucial roles in both processes.[3-7]

Diabetes and VEGF release

Prolonged elevation of blood glucose levels and accumulation of oxidative stress (by the increased formation of oxygen-free radicals and suppression of their removal) contributes to swelling and death of endothelial cells (ECs), thickening of the basement membrane (BM), loss of vascular pericytes, and increased synthesis of VEGF.[2,6,8,9]

Some of the earliest microvascular changes that occur in DR are the breakdown of the blood - retinal barrier (BRB), vasoregression, and the impairment of neurovascular coupling.[2] Tight junction (TJ) - associated proteins are key dynamic regulators of the BRB.[6,9] BRB breakdown is mediated primarily by VEGF.[9] Several cell types in the retina (such as pericytes, retinal pigment endothelium [RPE], and endothelial, glial, Müller, and ganglion cells) express VEGF, although Müller cell - derived VEGF seems to be primarily responsible for BRB breakdown and neovascularization.[4,7] During VEGF-induced breakdown of the BRB, protein kinase C (PKC) beta is activated and phosphorylates the TJ protein occludin. Additional junction-associated proteins, such as beta-catenin, claudin-5, zonula occludens-1, and connexin 43 are also phosphorylated in response to VEGF-A. These events lead to ubiquitin-mediated endocytosis of TJ components and to disassembly of the TJs - thereby contributing to increased vascular permeability.[2,3,7] Reduced retinal perfusion and retinal pericyte loss eventually lead to EC degeneration, microvascular destabilization, and perfusion alterations.[5] Dysfunction of ionic channels located in the retinal arteriolar vascular smooth muscle cells (BK channels) also causes retinal

The Retina

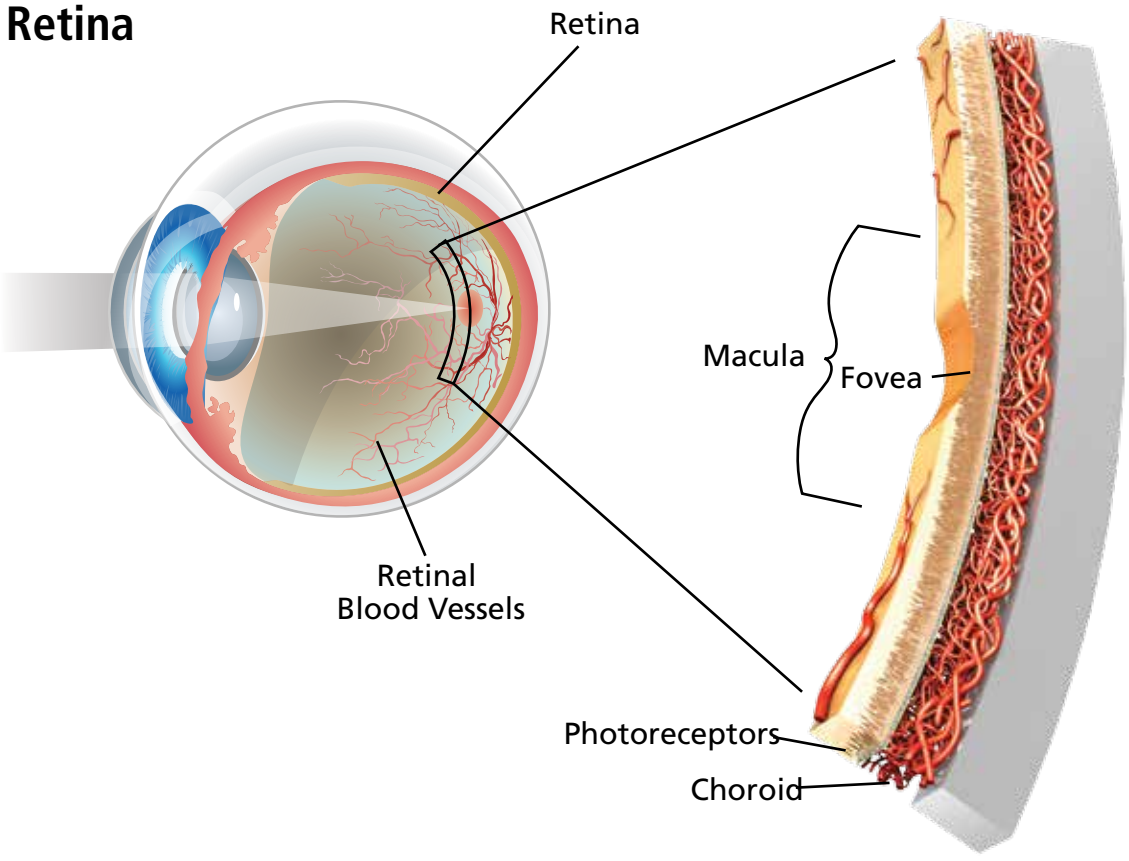

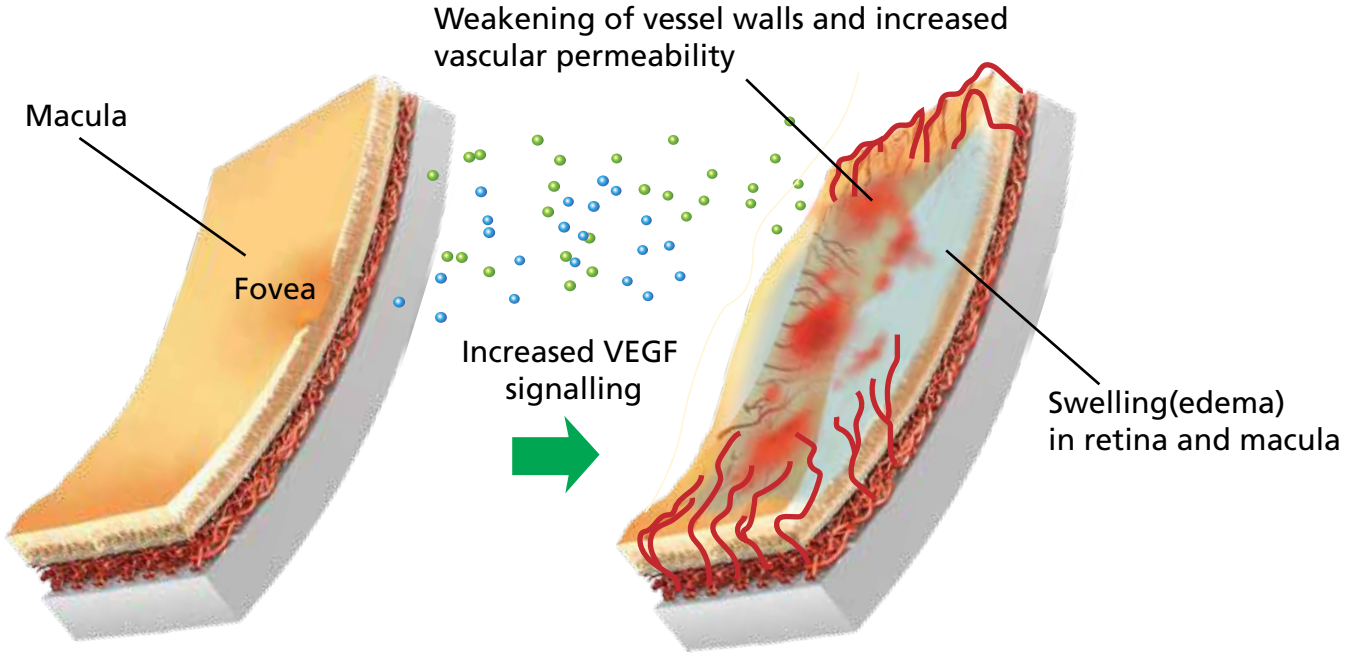

vasoconstriction during early phases of DR.[5] Additionally, VEGF-A upregulates the expression of adhesive molecules, promoting inflammatory cell adhesion to the endothelium.[6,9] The accumulation of leukocytes (leukostasis) on the luminal surface of the retinal capillaries is thought to be a major contributor and early event in BRB dysfunction.[5,8] Leukocyte adhesion causes endothelial dysfunction and reduced capillary perfusion. Leukostasis has been found to induce the disorganization of the vascular endothelial-cadherin/catenin complex and to produce reactive oxygen species (ROS) and inflammatory cytokines, leading to increased vascular permeability.[9]

Breakdown of the BRB and leakage from dilated and hyperpermeable capillaries lead to retinal thickening and eventually to macular edema. DME can occur at any stage of DR and is associated with many of the DR features such as pericyte loss, BM thickening, EC cell damage, MAs, increased vascular permeability, and leukostasis.[9]

References

1. Cheung N, Mitchell P, Wong TY. Diabetic retinopathy. *Lancet.* 2010;376:124-136.

2. Cunha-Vaz J, Ribeiro L, Lobo C. Phenotypes and biomarkers of diabetic retinopathy. *Prog Retin Eye Res*. 2014;41:90-111.

3. Zhang X, Bao S, Hambly BD, Gillies MC. Vascular endothelial growth factor-A: a multifunctional molecular player in diabetic retinopathy. *Int J Biochem Cell Biol.* 2009;41:2368-2371.

4. Antonetti D, Klein R, Gardner TW. Diabetic retinopathy. *N Engl J Med.* 2012;366:1227-1239.

5. Barot M, Gokulgandhi MR, Patel S, Mitra AK. Microvascular complications and diabetic retinopathy: recent advances and future implications. *Future Med Chem.* 2013;5:301-314.

6. Miller JW, Le Couter J, Strauss EC, Ferrara N. Vascular endothelial growth factor A in intraocular vascular disease. *Ophthalmology*. 2013;120:106-114.

7. Simo R, Sundstrom JM, Antonetti DA. Ocular anti-VEGF therapy for diabetic retinopathy: the role of VEGF in the pathogenesis of diabetic retinopathy. *Diabetes Care.* 2014;37:893-899.

8. Boyer DS, Hopkins JJ, Sorof J, Ehrlich JS. Anti-vascular endothelial growth factor therapy for diabetic macular edema. *Ther Adv Endocrinol Metab.* 2013;4:151-169.

9. Zhang X, Zeng H, Bao S, Wang N, Gillies M. Diabetic macular edema: new concepts in patho-physiology and treatment. *Cell Biosci.* 2014;4:27.